

Advancing Health

A CASE STUDY from MedStar Washington Hospital Center

Alternative to Cervical Fusion

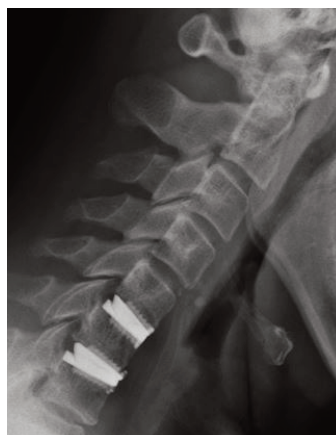2-Level Cervical Disc Replacement for Cervical Radiculopathy

Oliver Tannous, MD

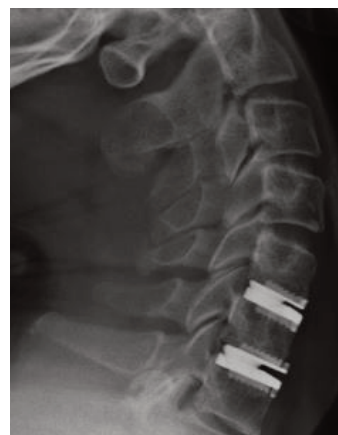MedStar Orthopaedic Institute spine surgeon at MedStar Washington Hospital Center focusing on disorders of the cervical, thoracic, and lumbar spine.

Abstract

A 61-year-old male physician presented with severe left arm pain and weakness due to cervical spondylosis and a cervical disc herniation. The patient underwent a two-level cervical disc replacement, which resolved his pain and weakness. The disc replacements also allowed him to retain the natural motion of his spine.



Disc Replacement Flexion



Disc Replacement Extension



**MedStar Washington
Hospital Center**

CASE STUDY

Alternative to Cervical Fusion

2-Level Cervical Disc Replacement for Cervical Radiculopathy

Patient Presentation

- A 61-year-old male physician presented with six weeks of severe, progressive, intolerable neck and left arm pain and weakness that prevented him from performing procedures.
- The patient was initially treated with an extensive course of NSAIDs, physical therapy, and cervical epidural injections. Since none of these treatments were successful in alleviating the pain, surgery became the last option.

Assessment


- X-rays indicated two levels of degenerative discs at C5-6 and C6-7. MRI confirmed the diagnosis and revealed severe stenosis of the C6 and C7 nerve roots in the neuroforamina. Imaging also showed that the facet joints at these levels were healthy. No spine deformity was present.
- Given that the disease was only confined to the discs and given the absence of a cervical deformity, the patient was a good candidate for a 2-level cervical disc replacement.

Pre-Operative Surgical Planning and Considerations

- The patient was presented with surgical options, including a traditional Anterior Cervical Discectomy and Fusion (ACDF) procedure, which locks the motion of the spine and places increased stress at adjacent levels, often accelerating adjacent disc degeneration.
- While a cervical disc replacement preserves the spine's natural motion, this procedure is not indicated for every patient. The surgeon must carefully evaluate the X-rays and MRI to determine if the operative degenerative levels are able to accept a disc replacement. This procedure requires attention to detail, as perfect implant placement is important.

Treatment

- The disc replacement was performed at C5-6 and C6-7 through a 1.5-inch incision hidden in his neck crease. No complications were experienced during the procedure.
- The patient was discharged the morning after surgery.
- He was placed in a soft collar for four days, but was encouraged to remove it and begin normal range of motion and normal activity of his neck.



Oliver Tannous, MD

"The vast majority of cervical spondylosis and cervical radiculopathy can be managed without surgery. It is the duty of the spine surgeon to undertake a conservative approach. When conservative measures fail, however, cervical disc replacement is an excellent option for certain patients, and can preserve the natural motion of the spine with a lesser chance of needing adjacent segment surgery in the future."

Outcome

- After 2 weeks, the pain and weakness mostly resolved, and at 6 weeks, the symptoms had nearly completely resolved.
- The patient has no limitations, and has returned to full preoperative exercises, activities, and work-related activity.

Conclusion

- Modern technological advances are allowing spine surgeons to

perform cervical disc replacements as opposed to fusions that have been the gold standard since the 1950s. Although disc replacements are proving to have many advantages over traditional fusion, they are not for every patient, and careful preoperative considerations are needed. In addition, this procedure requires attention to detail in order to recreate the spine's natural motion.

Non-Profit
Organization
U.S. Postage
PAID
MedStar Washington
Hospital Center



MedStar Washington Hospital Center
110 Irving St., NW
Washington, DC 20010

To refer a patient, or to schedule an informational interview with Dr. Tannous, please call **855-205-0972**.

To learn more about MedStar Orthopaedic Institute at MedStar Washington Hospital Center, visit **MedStarWashington.org/Orthopaedics**.

For a complete list of MedStar Orthopaedic Institute providers, visit **MedStarOrthopaedicInstitute.org**.

MedStar Washington Hospital Center is a 912-bed, major teaching and research hospital. It is the largest private, not-for-profit hospital in the nation's capital, among the 100 largest hospitals in the nation and a major referral center for treating the most complex cases.

